

Joints

CLASS SET!

Joints, or articulations, are structures in the skeleton where two or more bones join together. Because different joints are built differently and therefore behave differently, anatomists have devised a scheme for classifying articulations. This exercise presents a common system of joint classification and challenges you to find examples of joint classes and the different types of movements that they allow. This exercise also offers you the opportunity to examine examples of specific joints of the body.

Before you begin

- Read the appropriate chapter in your textbook.
- Set your learning goals. When you finish this exercise, you should be able to:
 - distinguish the three classes of joints
 - describe examples of each joint class
 - identify different types of motions in joints
 - describe the structure of the different joints
- Prepare your materials:
 - human skeleton (articulated)
 - synovial joints (model or fresh animal specimen l.s., knee or shoulder)
 - computer setup with DISSECTIBLE HUMAN or similar human dissection program (optional)
- Read the directions and safety tips for this exercise *carefully* before starting any procedure.

A. Classifying joints

Find an example of each type of joint described in the following steps. Try to find examples other than those given here.

SAFETY FIRST!

Use caution when handling the articulated skeleton.

- 1 Fibrous joints** are found where fibrous connective tissue tightly binds the articulating bones. Identify these types of fibrous joints (Figure 16-1):
 - Suture**—This is a joint between two flat bones, as between the left and right parietal bones (sagittal suture)
 - Syndesmosis**—These are bands of fibrous tissue that bind bones, as between the distal ends of the radius and ulna
 - Gomphosis**—A fibrous membrane that connects each tooth to its socket in a jaw's alveolar process
- 2 Cartilaginous joints** are formed when a mass of cartilage joins bones.
 - Synchondrosis**—Hyaline cartilage that connects bones; for example, the costal cartilage connection between a rib and the sternum
 - Symphysis**—Fibrocartilage that forms the joint, as in the symphysis pubis, joining left and right coxae
- 3 Synovial joints** are always **freely movable** (*diarthrotic*) joints. A flexible *joint capsule*, composed of ligaments and other connective structures and lined with a lubricating *synovial membrane*, allows a wide range of movement. Categories of synovial joints are based on the way in which the articulating bones fit together:
 - Gliding joint**—Two flat surfaces that slide past each other, as between two carpal bones
 - Hinge joint**—As with a door hinge, two bones are joined so that they can move in one plane only, as in the elbow
 - Ellipsoid joint**—An oval condyle that fits into an oval fossa, allowing movement in two planes, as between the metatarsals and phalanges of the foot
 - Pivot joint**—One bone that pivots on the axis of another, allowing rotation, as with the atlas and axis
 - Saddle joint**—Two saddle-shaped processes that fit together to allow movement in two planes, as between the thumb's proximal phalanx and the trapezium of the wrist
 - Ball-and-socket joint**—A ball-shaped process that fits into a rounded fossa, allowing almost unrestricted movement, as between the femur and the acetabulum

HINT

Fibrous and cartilaginous joints can be classified according to function rather than structure. Thus functional categories of **immovable** (synarthrotic) and **slightly movable** (amphiarthrotic) are sometimes used. Most fibrous joints are immovable, so they are called *synarthroses*. Likewise, many cartilaginous joints are slightly movable, so they are called *amphiarthroses*.

B. Examples of synovial joints

In this activity, you are challenged to explore the detailed anatomy of the human knee joint and the human shoulder joint. Find the structures listed in models or charts.

HINT

Use the diagrams given in the figures here, as well as those found in your textbook, for help in locating the major structures listed in this activity.

HINT

Using the DISSECTIBLE HUMAN or similar computerized human dissection program, explore the human body and try to find the structures listed in this activity.

- 1 In a model or chart of the human knee, identify these features (Figure 16-2):
 - Articular cartilage
 - Lateral meniscus
 - Synovial membrane
 - Patella
 - Condyles of tibia
 - Condyles of femur
 - Prepatellar bursa
 - Suprapatellar bursa
 - Posterior cruciate ligament
 - Anterior cruciate ligament
 - Tibial collateral ligament
 - Fibular collateral ligament
 - Patellar ligament
 - Head of fibula

How many of these features can you palpate in your own knee?
- 2 In a model or chart of the human shoulder joint, identify these features (Figure 16-3):
 - Acromion process of scapula
 - Coracoid process of scapula
 - Articular cartilage of humerus
 - Glenoid cavity
 - Articular cartilage of glenoid cavity
 - Medial glenohumeral ligament
 - Superior glenohumeral ligament
 - Acromioclavicular ligament
 - Subdeltoid bursa
 - Synovial membrane
 - Synovial cavity

C. Dissection of a joint

In a preserved or fresh animal specimen (l.s.) of a synovial joint, such as the knee or shoulder, identify the features described. Sketch your observations on a piece of paper and attach it to Lab Report 16.

SAFETY FIRST!

Because fresh animal tissue at room temperature may harbor bacterial colonies, handle your specimen with gloved hands.

- 1 Identify the *articulating bones*. Which joint is this?
- 2 Find the *articular cartilage* on the articulating surfaces of the joint. How would you describe its texture? What is the function of articular cartilage?
- 3 Locate the *ligaments* and other connective tissues of the *joint capsule* holding the joint together. Note how strong and how flexible they are.
- 4 The *synovial membrane* lines the joint capsule. What is its consistency? Is any *synovial fluid* still in the *synovial cavity* formed by this membrane? What is this fluid's function?

D. Joint movement

Although synovial, or *diarthrotic* joints, can allow a wide range of motion, they are limited by the structure of the joint and surrounding body parts.

Demonstrate the types of joint movement listed by performing them yourself.

SAFETY FIRST!

Be careful to avoid accidentally hitting someone as you do this activity. Do not attempt this activity if you have a physical condition that may be worsened by joint movements.

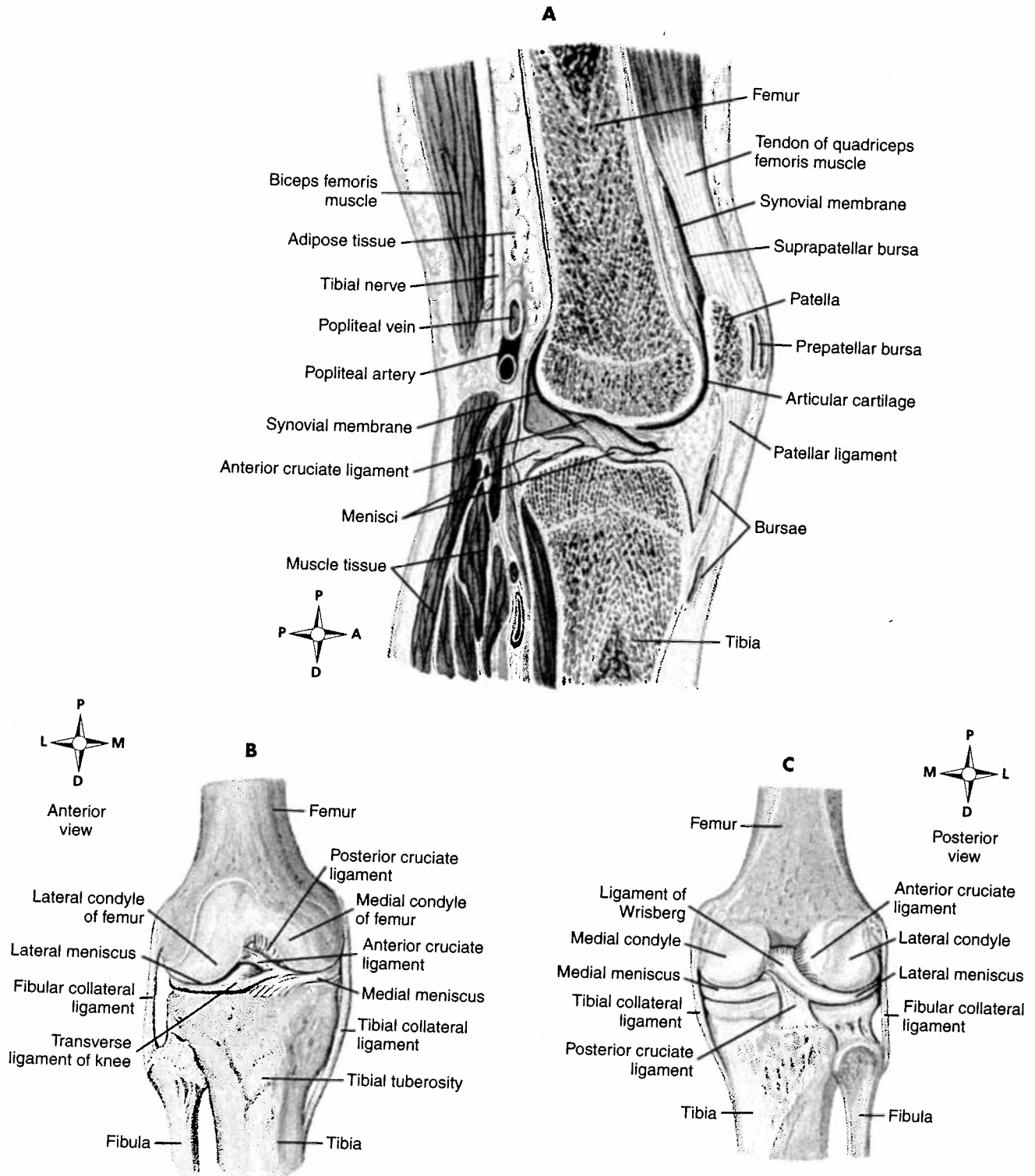


Figure 16-2 The human knee joint. **A**, Sagittal section of the knee. **B**, Anterior view, with superficial structures removed. **C**, Posterior view, with superficial structures removed.

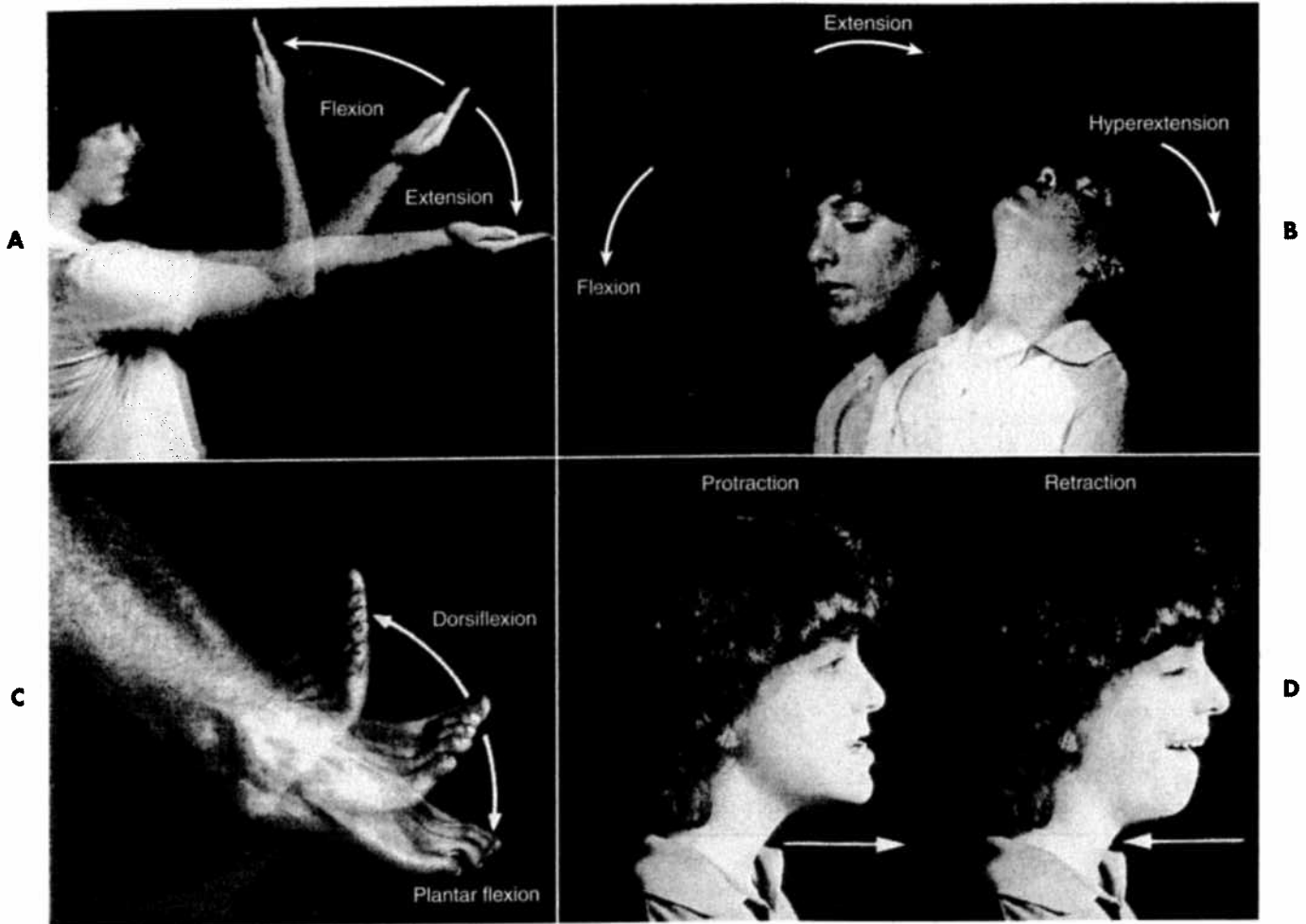
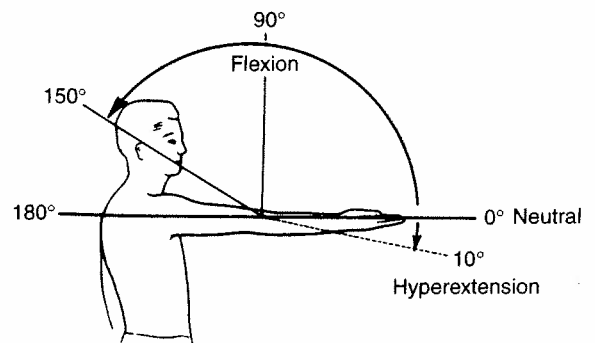


Figure 16-4 Movements relative to a coronal (frontal) plane. **A**, Flexion and extension of the elbow. **B**, Flexion, extension, and hyperextension of the neck. **C**, Dorsiflexion and plantar flexion. **D**, Protraction and retraction of the jaw.

- 1 Some skeletal movements involve movement of body parts relative to a coronal (frontal) plane (Figure 16-4):
- Flexion**—Decreasing the angle of a joint
 - Extension**—Increasing the angle of a joint
 - Hyperextension**—Moving a joint beyond its normal range or beyond the anatomical position
 - Dorsiflexion**—Bending the ankle so that the toes point upward
 - Plantar flexion**—Bending the ankle so that the toes point downward
 - Protraction**—Moving a part anteriorly, along a horizontal plane
 - Retraction**—Moving a part posteriorly, along a horizontal plane

HINT

The angle of movement in joints is measured in the manner shown:



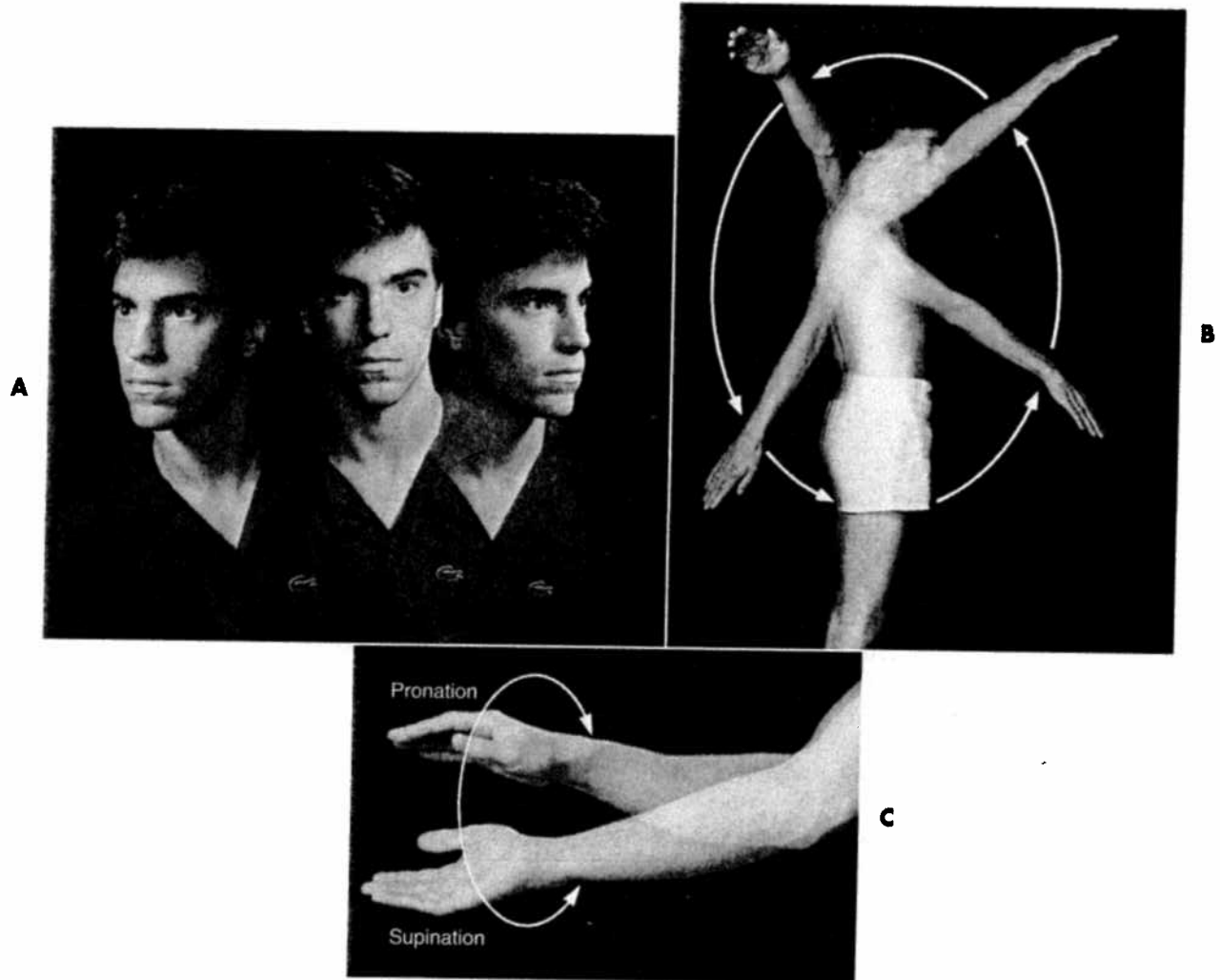


Figure 16-6 Circular movements. **A**, Rotation of the head. **B**, Circumduction of the arm. **C**, Pronation and supination of the hand.

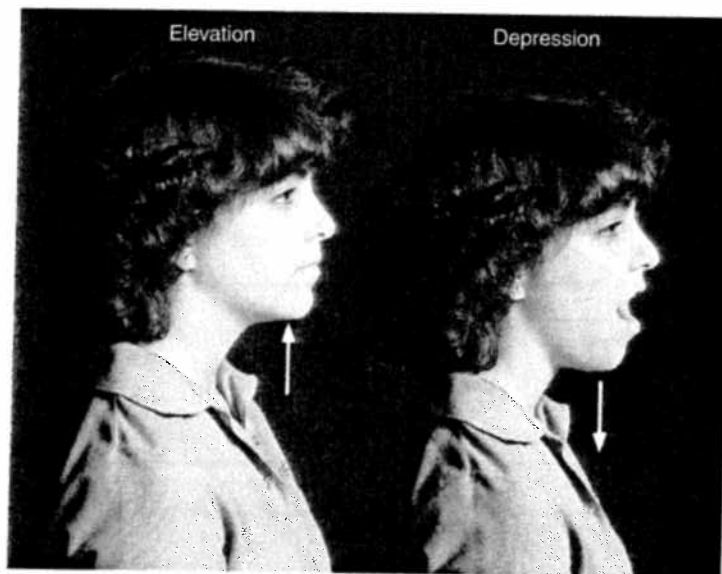


Figure 16-7 Special movements.

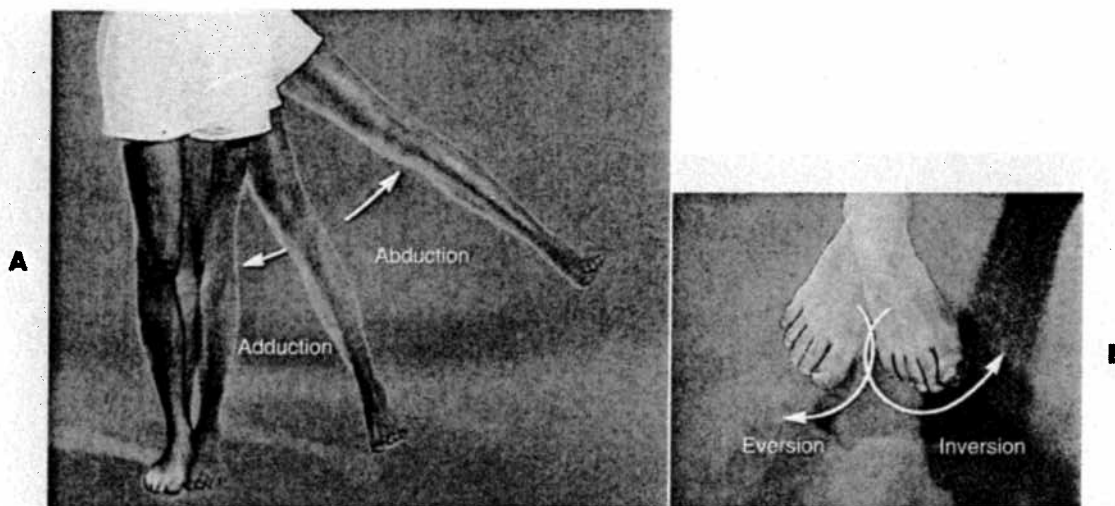


Figure 16-5 Movements relative to a sagittal plane. **A**, Adduction and abduction of the thigh. **B**, Eversion and inversion of the foot.

- 2 Some motions are done relative to a sagittal plane (Figure 16-5):
 - **Abduction**—Moving an appendage's distal end away from the midsagittal plane
 - **Adduction**—Moving an appendage's distal end toward the midsagittal plane
 - **Inversion**—Moving the foot from the anatomical position (sole downward) to a position in which the sole is facing the midsagittal plane
 - **Eversion**—Moving the foot from the anatomical position to a position in which the sole faces away from the midsagittal plane

- 3 Try these circular movements (Figure 16-6):
 - **Circumduction**—Moving the distal end of an appendage in a circle, making a cone-shaped sweep
 - **Rotation**—Moving a bone on its axis, as if on a pivot or axle
 - **Pronation**—Rotating the forearm from the anatomical position (palm forward) to reverse it (palm facing the posterior)
 - **Supination**—Rotating the forearm from the pronated position back to the anatomical position

- 4 Try these special movements (Figure 16-7):
 - **Elevation**—Raising a part
 - **Depression**—Lowering a part

HINT

These joint movements are commonly classified in other ways as well. For example, what scheme of classification is used in the textbook?

COLORING EXERCISE

Using colored pens or pencils, shade in the figure and accompanying labels in contrasting colors of your choice as indicated by the red numerals.

Joint Classification

FIBROUS JOINT 1

CARTILAGINOUS JOINT 2

SYNOVIAL JOINT

ARTICULATING BONE 3

ARTICULAR CARTILAGE 4

SYNOVIAL MEMBRANE 5

SYNOVIAL CAVITY 6

SYNOVIAL CAPSULE 7

SYNOVIAL JOINT TYPES

GLIDING 8

HINGE 9

ELLIPSOID 10

PIVOT 11

SADDLE 12

BALL AND SOCKET 13

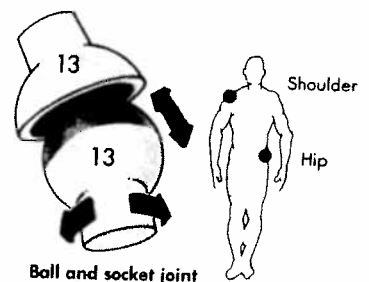
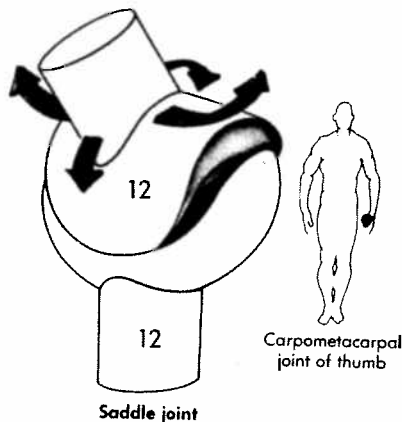
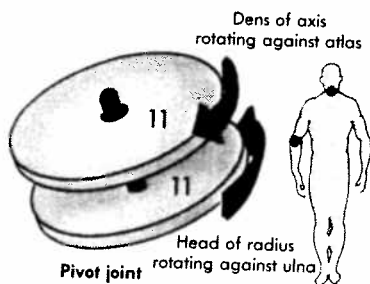
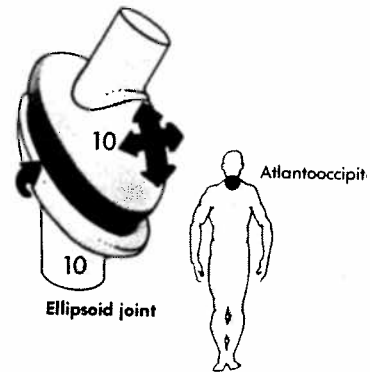
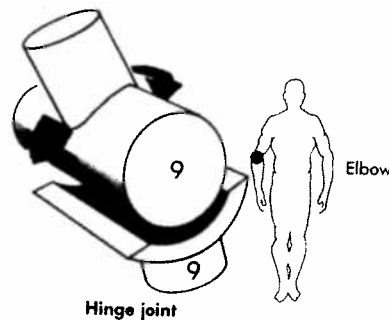
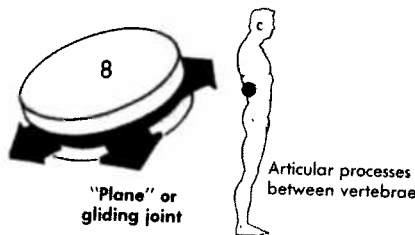
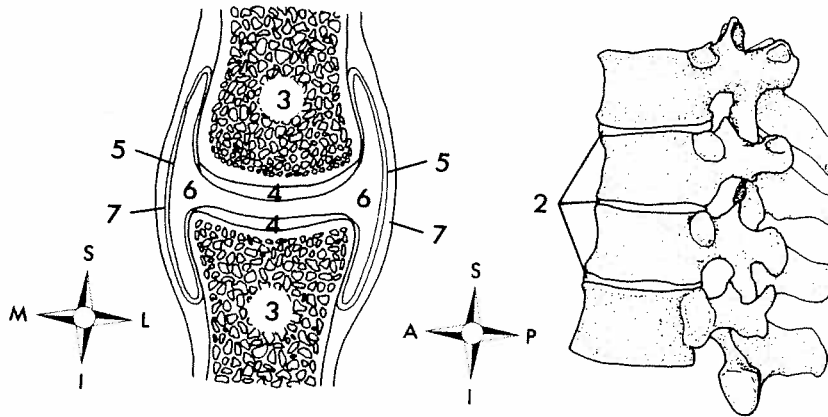
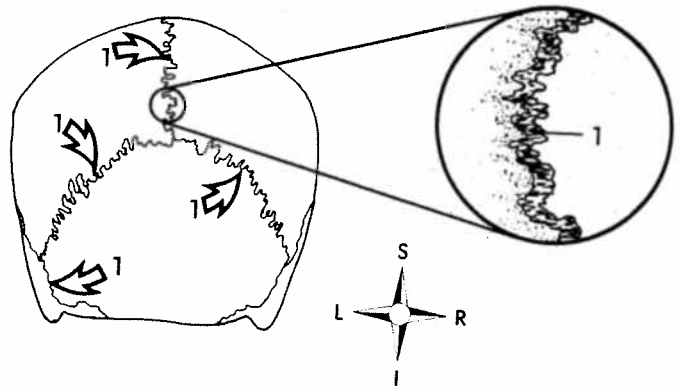


Figure 16-1 Joint structures and types.

LAB REPORT 16

Joints

Figure 16-8

- 1. _____
- 2. _____
- 3. _____

Matching I

- 1. _____
- 2. _____
- 3. _____
- 4. _____
- 5. _____
- 6. _____
- 7. _____
- 8. _____
- 9. _____
- 10. _____

Matching II

- 1. _____
- 2. _____
- 3. _____
- 4. _____
- 5. _____
- 6. _____
- 7. _____
- 8. _____
- 9. _____
- 0. _____

Matching I (may be used more than once)

- a. Fibrous joint
- b. Synovial joint
- c. Cartilaginous joint

- 1. Gliding joint
- 2. Synchrondrosis
- 3. Freely movable
- 4. Suture
- 5. Gomphosis
- 6. Saddle joint
- 7. Hinge joint
- 8. Symphysis
- 9. Mainly hyaline cartilage or fibrocartilage
- 10. Ellipsoid joint

Matching II (match these examples to their types)

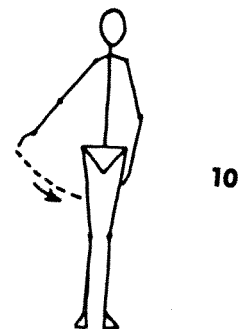
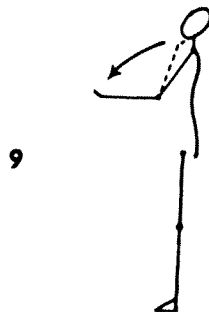
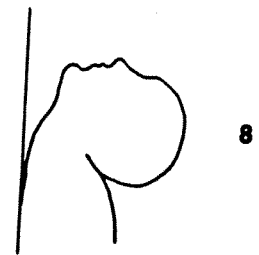
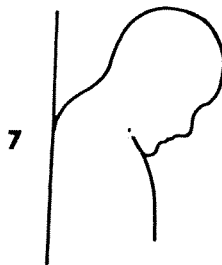
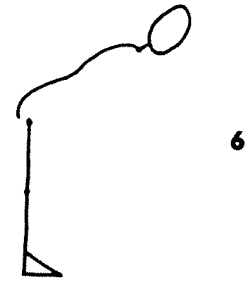
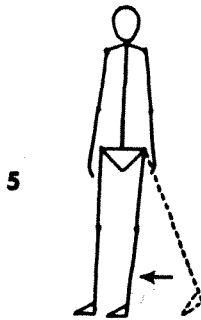
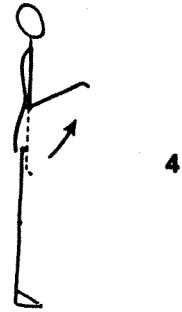
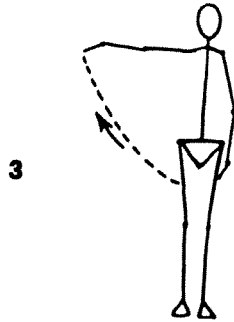
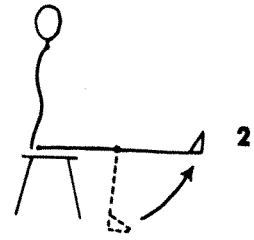
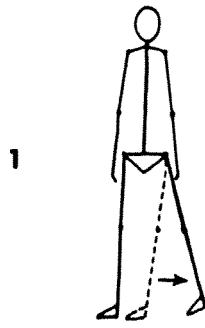
- a. Suture
- b. Syndesmosis
- c. Gomphosis
- d. Synchrondrosis
- e. Symphysis
- f. Hinge
- g. Gliding
- h. Pivot
- i. Saddle
- j. Ball and socket

- 1. Between bodies of vertebrae
- 2. Between the distal ends of the tibia and fibula
- 3. At the base of the thumb's proximal phalanx
- 4. Between the articular facets of the vertebrae's processes
- 5. Between the true ribs and sternum
- 6. Between the talus and lower leg
- 7. Between C1 and C2, at the dens
- 8. The shoulder
- 9. The transverse palatine suture
- 10. Between the tooth and jaw

Identify

1. _____
2. _____
3. _____
4. _____
5. _____
6. _____
7. _____
8. _____
9. _____
10. _____

Identify (In the blanks that follow, write the type of motion illustrated in the matching figure to the right. For example, in #1 is *abduction* or *adduction* shown?)



IV. Gymnastic Joints (Range of Motion)

Examiner (PT): _____

Circle the arm and leg used:

Dominant Arm: R L

Dominant Leg: R L

Arc of Movement (degrees)

	Start	Finish	Total
Elbow			
Wrist			
Index Finger			
Knee			
Dorsiflexion			
Plantar Flexion			

1. Compare your range of motion results with the normals posted at the the front of the room. Were there any joints in which your range of motion was less that normal? More than normal? Explain
2. What do you think are some factors that might affect range of motion in a joint?
3. How do you think range of motion might affect the likelihood of an injury occurring?
4. Why does the shoulder have greater motion than the hip (both ball and socket joints)?